



Long Overall Survival in a Case of Refractory Stage IV Squamous Cell Carcinoma of Lung Treated with Personalized *De Novo* Combination Regimen

Ajay Srinivasan, Pradip Devhare, Dadasaheb Akolkar*, Darshana Patil, Vineet Datta, Ashwini Ghaisas, Chirantan Bose, Shankar Somashekar, Revati Patil, Jinumary John, Sanket Patil, Sachin Apurwa, Navin Srivastava and Rajan Datar

Department of Cancer, Datar Cancer Genetics Limited, India

Abstract

We present here the case of a 61-year old male smoker diagnosed with aggressive metastatic Squamous Cell Carcinoma (SCC) of the Lung. The disease had progressed following failure of prior systemic lines of Standard of Care (SoC) therapies. Freshly biopsied tumor samples were obtained and used for multi-analyte molecular and functional interrogation of the tumor (ETA: Encyclopedic Tumor Analysis). Based on findings of ETA, iterations of *de novo* combination therapy regimen were administered to the patient to counter disease evolution, emergent drug resistance and disease progression. Based on such personalization of treatment regimen, timely therapeutic course correction could be effectively achieved. This case shows that ETA-guided sequential personalized prescription of cytotoxic and targeted therapies helped to counter disease progression at each instance and led to durable treatment response for 15 months.

Keywords: SCC; Lung; Personalized treatment; FGFR1; Pazopanib

Introduction

Squamous Cell Carcinoma (SCC) of the Lung accounts for 20% of all cases of Non-Small Cell Lung Cancer (NSCLC) is closely associated with cigarette smoking as well as other causes such as radiation, arsenic, and chloromethyl ether exposure [1]. Although surgical resection of pliant lesions is considered optimal for reducing tumor burden, this option is unviable in cases presenting with locally advanced (unresectable) or metastatic disease. Majority of NSCLC cases, including SCC are detected at a late stage wherein surgery is unviable. In such cases, loco regional radiation and systemic therapy options guided by Standard of Care (SoC) guidelines vary between the subtypes [2,3]. While lung Adenocarcinomas (AD) have more options, the same is not true for SCC of the lung, which is also generally more aggressive. While there are several molecular alterations in lung AD such as Single Nucleotide Variations (SNV) in EGFR or ALK - ROS - RET gene fusions which are indicative for selection of targeted therapy (such as Tyrosine Kinase Inhibitors, TKIs) [4], there are no such known indications in SCC [5]. Thus cytotoxic anticancer agents (chemotherapy) are the only presently available drug choices for Lung SCC and are associated with low response rates. In absence of viable treatment options and owing to aggressiveness, Lung SCC is associated with poor outlook. In this case report we describe a 61 year old male with history of smoking who had consistent tumor progression for over 12 months. The patient was administered personalized combination treatments based on *de novo* patient-derived evidence obtained by multi-analyte profiling of the tumor [6]. Such an approach facilitated timely therapeutic course correction to counter tumor progression and drug resistance.

Case Presentation

During late February 2017, a 61-year old male smoker was detected with a large mass in the lower lobe of left lung along with metastases in hilar and para tracheal lymph nodes and multiple hepatic patches. Computerized Tomography (CT) scan guided biopsy followed by Histopathological Examination (HPE) of biopsied tissue confirmed the diagnosis as poorly differentiated Squamous Cell Carcinoma (SCC). Based on the findings of HPE, the patient was administered 3 cycles of standard dose Gemcitabine and Cisplatin. Follow up PET-CT in September 2017 indicated disease progression with appearance of new hepatic metastases. The patient subsequently received 6 cycles

OPEN ACCESS

*Correspondence:

Dadasaheb Akolkar, Department of Cancer, Datar Cancer Genetics Limited, F-8, D-Road, Ambad, Nashik, 422010, Maharashtra, India, E-mail: dadasaheb.akolkar@datarpgx.com

Received Date: 12 Aug 2020

Accepted Date: 08 Sep 2020

Published Date: 14 Sep 2020

Citation:

Srinivasan A, Devhare P, Akolkar D, Patil D, Datta V, Ghaisas A, et al. Long Overall Survival in a Case of Refractory Stage IV Squamous Cell Carcinoma of Lung Treated with Personalized *De Novo* Combination Regimen. *Clin Case Rep Int.* 2020; 4: 1180.

Copyright © 2020 Dadasaheb

Akolkar. This is an open access article distributed under the Creative Commons Attribution License, which permits unrestricted use, distribution, and reproduction in any medium, provided the original work is properly cited.

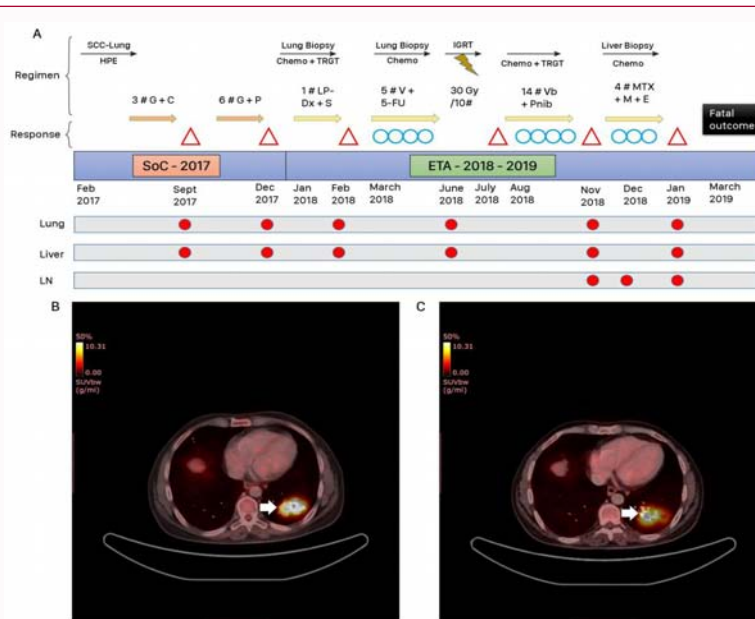


Figure 1: (A)Timeline of events. SCC: squamous cell carcinoma; HPE: Histopathological examination; Chemo + TRGT: Chemotherapy + Targeted; LBx: Liquid biopsy; CTC-Chemo: CTC based Chemosensitivity; IGRT: Image-Guided Radiation Therapy; G +C: Gemcitabine + Cisplatin; G+P: Gemcitabine + Paclitaxel; V = 5-FU: Vinorelbine + 5-Fluorouracil; Vb + Pnib: Vinblastine + Pazopanib; MTX + M + E: Methotrexate + Mitomycin + Etoposide; SoC: Standard of care; ETA: Encyclopedic tumor analysis; Δ : progression/recurrence; \circ : Treatment response/stable disease; \bullet : Presence of malignant mass at various sites; Lung, Liver and LN: lymph node (B,C): Encyclopedic Tumor Analysis (ETA) guided treatment response evaluated stable disease in Positron emission tomography-computed tomography (PET-CT) scan. Baseline (B) and last follow-up scans (C) are in left and right panels, respectively. Primary malignant lesion in left lower lobe of the lung is indicated by white arrow.

of standard dose Gemcitabine and Paclitaxel until November 2017. However, a follow up PET-CT scan in December 2017 revealed continued disease progression with increase in size of primary mass lesion in left lower lobe of the lung as well as increase in size of hepatic metastatic lesions, indicating no response to chemotherapy. The patient was initially referred to palliative care.

Subsequently, the patient underwent a biopsy of the lung lesion to obtain tumor tissue sample. The freshly biopsied tissue sample along with 15 ml of peripheral blood was provided to the study sponsor to perform ETA. Timeline of events during disease management are summarized in Figure 1A. ETA revealed FGFR1 copy number gain (6 copies) as a major molecular alteration while *in vitro* chemosensitivity profiling of viable cells indicated higher sensitivity to Doxorubicin. There were no EGFR mutations or ALK gene rearrangements detectable by Next Generation Sequencing. The tumor sample was negative for PD-L1 expression by Immunohistochemistry (IHC). Based on these findings (Table 1), the combination regimen of low dose Sunitinib and Liposomal Doxorubicin (Lipo-Dox) were recommended to the patient. The patient received 1 cycle of Lipo-Dox but defaulted from Sunitinib. Subsequently, Progression of Disease (PD) was observed within 30 days with appearance of new lesion in segment VI of the liver.

The patient underwent repeated biopsy of the lung lesion to obtain fresh tissue. However, due to insufficient content, molecular analysis was not feasible. However *in vitro* chemosensitivity profiling of viable tumor cells indicated high response towards 5-fluorouracil and Vinorelbine.

Based on these findings, patient received 5 cycles of Vinorelbine (40 mg) and 5-fluorouracil (750 mg) until June 2018 during which Stable Disease (SD) was observed radio logically at follow-up scans. In June 2018, the patient underwent Trans Arterial Chemo

Table 1: Major molecular alterations identified in Patient with SCC lung after ETA.

| Sample Type Received | Gene Name | Molecular alteration |
|-----------------------|------------------------|----------------------|
| (Lung biopsy) | FGFR1 | CNV (gain 6) |
| | RAD50 | CNV (gain 3) |
| | CDK4 | DGE (2.9x) |
| | VEGFA | DGE (2.3x) |
| | PD-L1 | Negative |
| February 2018 (Blood) | GNAS p. R201H | SNV (0.5% MAF) |
| | CDK6 | DGE (2.5 x) |
| | BCR | DGE (2.8x) |
| December 2018 (Blood) | TP53 p. G325* | SNV (41% MAF) |
| | FGFR1 | CNV (gain) |
| (Liver biopsy) | ATM c.1236-2A>T | SNV (4.6% MAF) |
| | MLH1, MSH2, MSH6, PMS2 | Intact |

MAF: Mutant Allele Frequency; SNV: Single Nucleotide Variation; CNV: Copy Number Variation; DGE: Differential Gene Expression

Embolization (TACE) for liver lesions. Owing to onset of Grade III neutropenia, the treating clinician requested a re-evaluation of the therapy options for administration post-TACE.

Owing to non-availability of biopsiable lesion, prior ETA data was reviewed and a combination of Pazopanib (based on FGFR1 gain) and Vinblastine (based on *in vitro* chemosensitivity) was recommended. The patient received 14 cycles of weekly Vinblastine (9 mg) + Pazopanib (400 mg, 1 OD) until November 2018 during which the patient continued to show radiologically SD (Figure 1B, 1C). There were no significant therapy related AEs, and the patient experienced transient mild/moderate fatigue, anorexia and thrombocytopenia. However, follow-up PET-CT scan at the end of November 2018

indicated appearance of left lobar lymph nodes as well as increase in size of primary and hepatic lesions which were suggestive of PD.

The patient underwent a repeat biopsy to obtain fresh tissue from liver lesion in December 2018. NGS of tumor tissue DNA detected SNV in ATM (c.1236-2A>T, MAF: 4.6%) while NGS of ctDNA showed TP53 p.G325* (MAF: 41%) and FGFR1 gain (n=7). IHC showed intact nuclear expression of DNA Mismatch repair markers (MLH1, MSH2, MSH6 and PMS2). *In vitro* chemo-sensitivity profiling of viable tumor cells showed high response to Methotrexate, Mitomycin and Etoposide. These drugs were recommended in combination therapy regimen (Methotrexate 60 mg IV, Mitomycin 30 mg IV, Tab-Etoposide 50 mg) as 4th line ETA guided therapy. However, the treatment had to be discontinued after 2 cycles owing to deterioration of patient's general condition and onset of Grade II pancytopenia. Follow-up PET-CT In January 2019 showed further disease progression leading to patient's death in March 2019.

Discussion

At present, the standard frontline treatment for Lung SCC remains exclusively chemotherapy. Although platinum-based chemotherapy remains the cornerstone of treatment of SCC-lung, the prognosis of patients with relapsed disease remains extremely poor, with limited treatment options. The case presented here is with advanced refractory disease and progressed on SoC therapies of Gemcitabine - Cisplatin (first line) and Paclitaxel-Gemcitabine Second line. ETA at different time intervals allowed timely therapeutic course correction to address disease progression.

The first iteration of ETA guided combination regimen was based on chemo sensitivity and FGFR1 copy number gain respectively. FGFR1 amplification was found to be predominant (20%) in squamous cell cancers of lung and rare in adenocarcinomas [8]. However, disease progression was observed and may speculatively be attributed to non-compliance. Though the second iteration of combination regimen led to 6 months PFS, it was discontinued owing to risks of myelosuppression. The third iteration re-attempted FGFR1 blockade with low dose Pazopanib along with Vinblastine and yielded 4 months' PFS. Pazopanib is a potent multi-TKI inhibitor and, as a single agent, has shown limited activity in non-SCC NSCLC patients [9]. Although the 4th iteration was initiated, it could not be administered due to deteriorating general condition of the patient.

In this case of Lung SCC, sequential ETA revealed constant FGFR1 gain against a relentlessly evolving molecular landscape of the tumor. However, the prolonged overall survival of ~15 months in metastatic Lung SCC indicates a significant 'outcome benefit' as compared to commonly documented median survival in such cases.

Metastatic NSCLC have limited treatment options and poor outcomes with a 5-year survival rate of about 1%. A significant proportion of metastatic cases are referred for palliative chemotherapy beyond failure of 1-2 lines of chemotherapy [10]. We attempted to address this therapeutic roadblock in a case of advanced refractory Lung SCC based on multi-analyte, molecular and functional profiling of the tumor to identify actionable vulnerabilities and treat the cancer with combination regimens. Based on such an approach of iterative treatment, the 15 months survival in metastatic SCC of Lung justifies a significant 'outcome benefit' as compared to commonly documented median survival in such cases.

Patient and Methods

Patient

The case described in this manuscript is a retrospective observational report of a single patient who opted to receive personalized cancer treatment based on Encyclopedic Tumor Analysis (ETA) approach [6]. The patient provided signed informed consent for the publication of de identified data and results. Sample collections and therapeutic interventions were carried out at HCG Manavata Cancer Centre, Nashik, India. Cellular and molecular investigations on the patient's samples were carried out at the College of American Pathologists (CAP) - accredited and International Organization for Standardization (ISO) - compliant facilities of Datar Cancer Genetics Limited (DCGL), Nashik, India. All interventional procedures including therapy administration were approved as per standard hospital practices and in concordance with existing ethical, medical and legal requirements.

Sample collection

Freshly biopsied tumor tissue (~ 5 mm × 5 mm × 5 mm) was transferred into 5 ml transport medium (that preserved the viability of tumor cells) and stored at 4°C. Fresh tissue was either processed immediately or cryopreserved at -80°C. 8 ml to 10 ml peripheral blood was collected by venous puncture in each of the Cell-Free DNA BCT[®] and EDTA vacutainer tubes. Blood was stored and transported at 4°C.

Encyclopedic tumor analysis

The process of ETA has been explained previously [6,7].

Acknowledgement

The Authors acknowledge the contribution of HCG-Manavata Cancer Centre, Nashik, India and their staff and thank them for the clinical management of the patient.

References

1. Raparia K, Villa C, DeCamp MM, Patel JD, Mehta MP. Molecular profiling in non-small cell lung cancer: A step toward personalized medicine. Arch Pathol Lab Med. 2013;137(4):481-91.
2. Govindan R, Bogart J, Vokes EE. Locally advanced non-small cell lung cancer: The past, present, and future. J Thorac Oncol. 2008;3(8):917-28.
3. Miller YE. Pathogenesis of lung cancer: 100 year report. Am J Respir Cell Mol Biol. 2005;33(3):216-23.
4. Stinchcombe TE. Targeted therapies for lung cancer. Cancer Treat Res. 2016;170:165-82.
5. Sos ML, Thomas R. Genetic insight and therapeutic targets in squamous-cell lung cancer. Oncogene. 2012;31(46):4811-4.
6. Nagarkar R, Patil D, Crook T, Datta V, Bhalerao S, Dhande S, et al. Encyclopedictumor analysis for guiding treatment of advanced, broadly refractory cancers: results from the RESILIENT trial. Oncotarget. 2019;10(54):5605-21.
7. Ranade A, Patil D, Bhatt A, Dhasare R, Datta V, Datar R, et al. Adaptive, iterative, long-term personalized therapy management in a case of stage IV refractory NSCLC. J Pers Med. 2019;9(3):34.
8. Weiss J, Sos ML, Seidel D, Peifer M, Zander T, Heuckmann JM, et al. Frequent and focal FGFR1 amplification associates with therapeutically tractable FGFR1 dependency in squamous cell lung cancer. Sci Transl Med. 2010;2(62):62ra93.
9. Weiss JM, Villarruz LC, Socinski MA, Ivanova A, Grilley-Olson J, Dhruva N, et al. A single-arm phase II trial of pazopanib in patients with

advanced non-small cell lung cancer with non-squamous histology with disease progression on bevacizumab containing therapy. *Lung Cancer*. 2014;86(2):288-90.

10. Spiro SG, Rudd RM, Souhami RL, Brown J, Fairlamb DJ, Gower NH, et

al. Chemotherapy versus supportive care in advanced non-small cell lung cancer: improved survival without detriment to quality of life. *Thorax*. 2004;59(10):828-36.